



**PATIENT PRESENTING CLINICAL SIGNS**

**PATIENT** Pixie Derbyshire History: Acute stranguria. History of FLUTS with previous ultrasound (5/24/22) showing urinary bladder sediment and negative urine culture.

**SPECIES** Physical Examination: N/A

Feline Urinalysis: Pending. Culture pending.

**BREED** CBC: N/A.

DSH Serum Biochemistry: N/A.

Radiographic Findings: N/A.

**SEX**

MN

**AGE**

8 years

**WEIGHT**

12.7 #

**ULTRASONOGRAPHIC EXAMINATION OF THE ABDOMEN**

**Urinary System**

Full urinary bladder with a normal thickness and appearance of the wall. Small amount of floating sediment evident. Focal dependent mildly shadowing hyperechogenic sediment. No uroliths present.

Normal trigone area, proximal urethra, and iliac blood vessels.

Normal iliac lymph nodes. Ureters not visualized.

**INTERPRETED BY**

Remo Lobetti, BVSc,  
MMedVet (Med), PhD, Dipl.  
ECVIM

**Reproductive System**

N/A.

**Adrenal Glands**

N/A.

**Spleen**

N/A.

**Liver**

N/A.

**Gastrointestinal**

N/A.

**Pancreas**

N/A.

**Free Abdomen**

No ascites.

**DATE**

7/12/22

**INVOICE**

303120

**IMAGING PERFORMED BY**

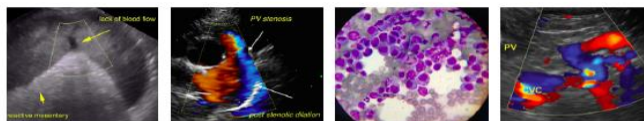
Dr Megan Cassels-Conway,  
DVM

**HOSPITAL NAME**

Central Broward Animal  
Hospital

**REFERRING VET**

Dr Oms, DVM



**PATIENT                      ULTRASONOGRAPHIC FINDINGS**

Pixie Derbyshire

Primary Findings:

- Urinary bladder sediment.

**SPECIES**

Secondary Findings:

Feline

- None.

**BREED**

DSH

**INTERPRETATION OF THE FINDINGS & FURTHER RECOMMENDATIONS**

**SEX**

Etiologies for the urinary bladder sediment would be crystalluria, sterile cystitis, bacterial cystitis, and small uroliths.

MN

**AGE**

Further assessment needs to be based on the pending results.

8 years

Current recommendations for the management of FLUTS is feeding a specific urinary diet such as Hills c/d stress and environmental enrichment.

**WEIGHT**

12.7 #

**INTERPRETED BY**

Remo Lobetti, BVSc,  
MMedVet (Med), PhD, Dipl.  
ECVIM

**IMAGING PERFORMED BY**

Dr Megan Cassels-Conway,  
DVM

**HOSPITAL NAME**

Central Broward Animal  
Hospital

**REFERRING VET**

Dr Oms, DVM

**INVOICE**

303120

**DATE**

7/12/22



**PATIENT**

Pixie Derbyshire

**SPECIES**

Feline

**BREED**

DSH

**SEX**

MN

**AGE**

8 years

**WEIGHT**

12.7 #

**INTERPRETED BY**

Remo Lobetti, BVSc,  
MMedVet (Med), PhD, Dipl.  
ECVIM

**IMAGING PERFORMED BY**

Dr Megan Cassels-Conway,  
DVM

**HOSPITAL NAME**

Central Broward Animal  
Hospital

**REFERRING VET**

Dr Oms, DVM

**INVOICE**

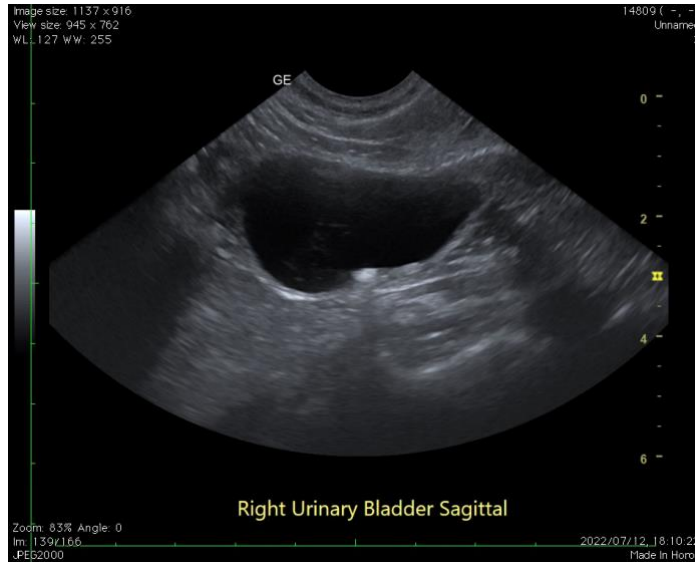
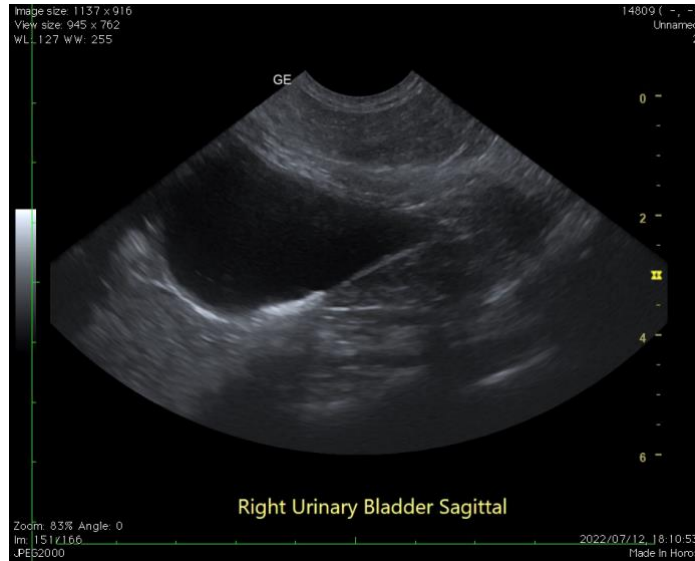
303120

**DATE**

7/12/22

**IMAGES**

**Urinary bladder**



**The information and recommendations provided are based on the images presented by the referring veterinarian. No evaluation can be communicated regarding pathology that was not visible in the image/video clips provided.**

Thank you for this referral. If the clinical or image interpretation does not parallel your findings or if I can be of any further assistance, please contact me.

**Remo Lobetti, BVSc, MMedVet (Med), PhD, Dipl. ECVIM (Internal Medicine)**  
[rlobetti@mweb.co.za](mailto:rlobetti@mweb.co.za)